

Clinical Foundations

*A Patient-focused Education Program
for Respiratory Care Professionals*



Advisory Board

Janet Boehm, EdD, MS, RRT
Director, Clinical Education
Youngstown State University
Youngstown, OH

Richard Branson, MS, RRT, FAARC
Associate Professor of Surgery
University of Cincinnati College of Medicine
Cincinnati, OH

Richard Kallet, MSc, RRT, FAARC
Clinical Projects Manager
University of California
Cardiovascular Research Institute
San Francisco, CA

Donna Hamel, RRT, FAARC
Clinical Research Coordinator
Duke University Health Systems
Raleigh-Durham, NC

Neil MacIntyre, MD, FAARC
Medical Director of Respiratory Services
Duke University Medical Center
Durham, NC

Tim Myers, BS, RRT-NPS
Pediatric Respiratory Care
Rainbow Babies and Children's Hospital
Cleveland, OH

Tim Op't Holt, EdD, RRT, AEC, FAARC
Professor, Department of Respiratory Care
and Cardiopulmonary Sciences
University of Southern Alabama
Mobile, AL

Ruth Krueger Parkinson, MS, RRT
Protocol/PI Coordinator
Sioux Valley Hospital
Sioux Valley, SD

Helen Sorenson, MA, RRT, FAARC
Assistant Professor, Dept. of Respiratory Care
University of Texas Health Sciences Center
San Antonio, TX

www.clinicalfoundations.org

Visit Clinical Foundations online at
www.clinicalfoundations.org
Archives • Free CRCEs

Management of the Difficult Airway


Irene Osborn, MD

Adequate airway management is crucial to the success of anesthesia, and special effort is often required for patients with difficult airways. The American Society of Anesthesiologists (ASA) Task Force defined a difficult airway as “the clinical situation in which a conventionally trained anesthesiologist experiences difficulty with mask ventilation, difficulty with tracheal intubation, or both.” This article reviews the identification and preparation of these patients and discusses the various treatment options for managing the failed intubation. Modern airway management has evolved with the introduction of supraglottic devices as well as newer techniques to facilitate endotracheal intubation. Device options reviewed here include the fiberoptic bronchoscope, rigid fiberoptic laryngoscopes, the lighted stylette, GlideScope or Video Macintosh video laryngoscopic systems, and the ViewMax fiberoptic laryngoscope. Bag and mask ventilation devices include the laryngeal mask airway, the Combitube, and the Rusch Easy Tube. The difficult airway continues to be an unexpected challenge in acute care medicine. Having a plan for management can reduce potential complications, respiratory-related malpractice lawsuits and improve outcomes.

Prehospital Management of the Difficult Airway

Prasanthi Ramanujam, MD and Gary M. Vilke, MD

Emergency care often involves rapid and effective management of the airway. As in hospital situations, the difficult airway requires special care, but with increased urgency to establish adequate oxygenation. This article reviews the identification of such patients, both adult and pediatric, and the methods of managing the difficult intubation and ventilation before arrival at the hospital. The first step in treating the patient with a difficult airway is providing adequate oxygen through devices such as the nasal cannula, face-mask or non-rebreather mask. The Bag Valve Mask (BVM) is the most important device for maintaining oxygenation and ventilation in most emergency settings. Rapid assessment of the difficult airway is critical and grading systems such as the Cormack-Lehane laryngeal view system and the Mallampati Score can facilitate in the management. Several rescue airway devices suitable for the prehospital emergency setting are described in this article. It is important for prehospital providers to be very familiar and comfortable with the available alternative airway devices and to maintain skill in their use during these situations.



Management of the Difficult Airway

Irene P Osborn, MD

Airway management is of paramount importance in any clinical setting. It must always be assessed first, and if any compromise or potential compromise is found, this must be dealt with as a first priority. Modern airway management has evolved with the introduction of supraglottic devices as well as newer techniques to facilitate endotracheal intubation. This discussion will explore the management of the difficult airway and the role of alternative airway devices for managing failed intubation or ventilation.

The American Society of Anesthesiologists (ASA) Task Force defines a difficult airway as “the clinical situation in

which a conventionally trained anesthesiologist experiences difficulty with mask ventilation, difficulty with tracheal intubation, or both.”¹ The Task Force further noted that the “difficult airway represents a complex interaction between patient factors, the clinical setting, and the skills and preferences of the practitioner.” The principal adverse outcomes associated with the difficult airway include (but are not limited to): death, brain injury, myocardial injury and airway trauma.

Mounting experience with difficult tracheal intubation in the anesthesia setting argues for a more methodical approach to individuals with anatomic and medical problems that might compli-

cate direct laryngoscopy. Consequently, the ASA published and updated clinical guidelines for dealing with patients who present a difficult airway and, in particular, an intubation challenge. (Figure 1)

The purpose of these guidelines is to facilitate the management of the difficult airway and to reduce the likelihood of adverse outcomes. Modified ASA guidelines have now been translated into other fields, including emergency medicine. It appears likely that difficult airway management and difficult tracheal intubation scenarios will become routinely promulgated ALS algorithms during the next decade—a respiratory standard of care for acute care practitioners.

The incidence of the difficult airway, difficult laryngoscopy and difficult intubation are not well defined. Difficulty with intubation is experienced more frequently during obstetrical anesthesia than general surgical anesthesia (7.9% versus 2.5%), but very difficult intubations are seen with a similar frequency in obstetrical and non-obstetrical surgical

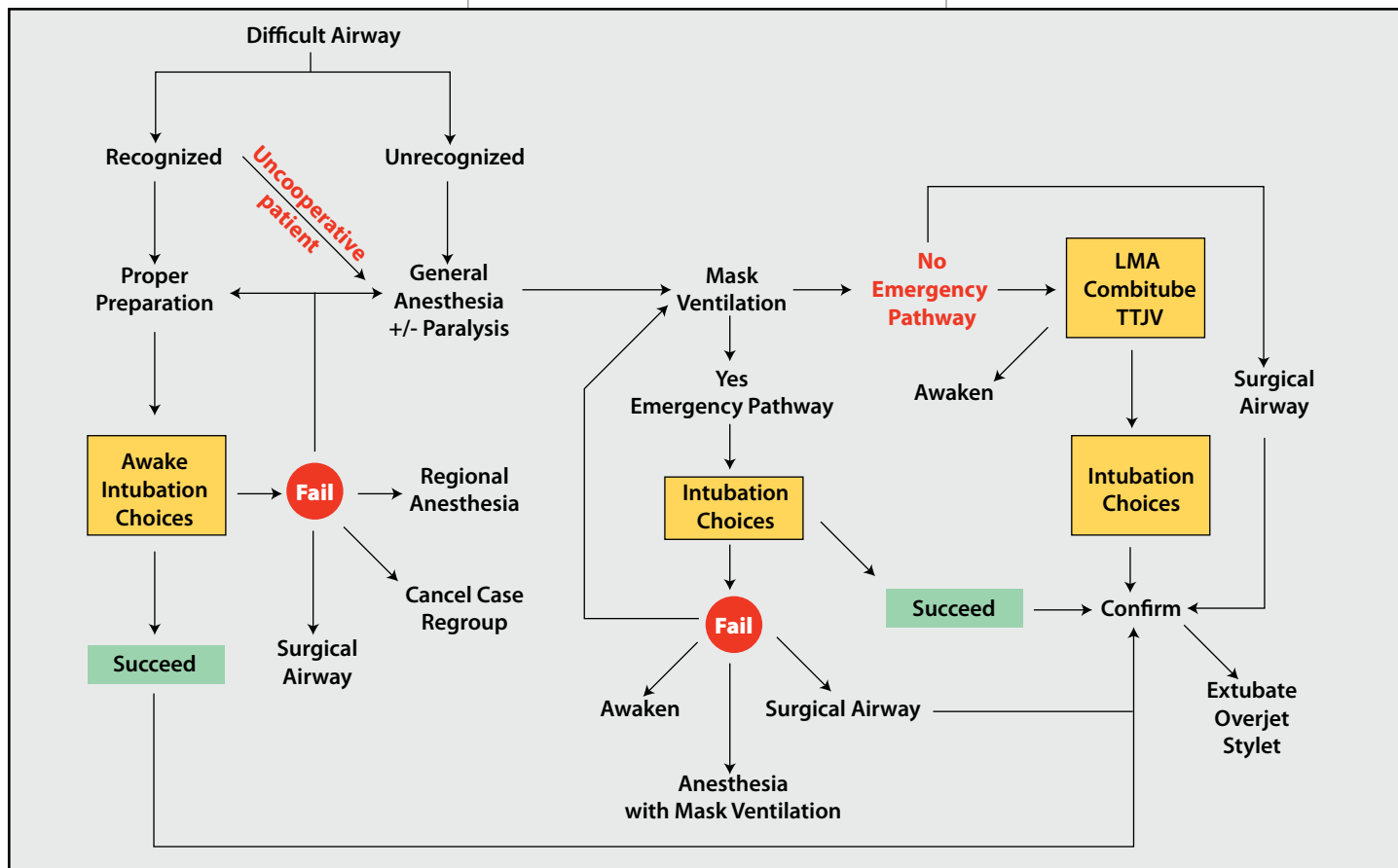


Figure 1. Clinical guidelines for managing the difficult airway. American Society of Anesthesiologists, updated 2002.

Table 1. ASA practice guidelines for difficult airway management

- Evaluation of the airway
- Preparation for difficult airway management
- Strategy from the start of anesthetic care
- Strategy at termination of anesthetic care
- Follow-up of patients

populations (2% versus 1.8%). The incidence of difficult mask ventilation is not well defined but appears to be much less than that of difficult intubation. In a non-obstetrical population, Rose reported an incidence of .01% whereas Benumof cited an incidence of .0001- .02%.²

Recognition of the difficult airway

The primary step in the Difficult Airway Algorithm is evaluation and recognition of the potentially difficult airway. It is estimated that between 1–3% of the patients who need endotracheal intubation have existing airway problems that makes this procedure difficult.³ Recognition of these difficult airways allows the clinician to proceed with caution and consider other options for airway maintenance. (Table 2) Evaluation of the airway is the first step in airway management and seeks to identify preoperatively the required degree of airway maintenance and protection and, more importantly, the nature and extent of any problems with airway management. (Table 3) All patients should have a basic evaluation consisting of history, general examination and a few specific tests. It is not a precise science and some of the benefit of airway evaluation is the clinical interaction with a patient and focus on a core duty of the anesthetist. In general surgical patients, evaluation will pick up only 15-50% of patients who have true clinically difficult intubations, and will also label a number of normal patients as being difficult. Some sub-specialties such as ENT, maxillofacial, orthopedic and neuroanesthesia have a much higher prevalence of difficult airways, which may derive from an airway disease process, and a

more thorough evaluation is required to ascertain the best primary and secondary plans for airway management.⁴

There are several physical signs that can alert one to the possibility or probability that a patient may have a difficult airway. The 6 “D’s” of airway assessment are one method used to evaluate for signs of difficulty:

- Disproportion (tongue to pharyngeal size/ Mallampati classification)
- Distortion (e.g. neck mass)
- Decreased thyromental distance (receding or weak chin)
- Decreased interincisor gap (reduced mouth opening)
- Decreased range of motion of the cervical spine
- Dental overbite

Difficult laryngoscopy can usually be predicted on physical examination, but unexpected difficult laryngoscopy can occur. Proper preparation for a difficult airway often involves awake intubation or a plan of action should this be challenging.

Basic Preparation for Difficult Airway Management

Airway patency. Assess the airway for signs of obstruction, foreign bodies, and obvious fractures. The most common object obstructing the airway is the tongue.

Breathing. Address the obvious: Respiration? Depth? Rate? Color of mucous membranes?

Patients can be divided into 4 groups, those requiring immediate, emergent, urgent and semi-elective management. Apneic patients require emergent airway management, whereas immediate airway management is required for patients in obvious respiratory distress. The sponta-

Table 2. Predictors of difficult tracheal intubation

- Mouth opening
- Thyromental distance
- Mallampati class
- Neck movement
- Ability to protrude the mandible
- History of difficult intubation

Table 3. Specific populations with increased incidence of difficulty

- The obstetrical airway
- The traumatized airway
- Obese patients
- C-spine injury (increased incidence of grade III laryngoscopic view)

neously breathing patient should receive supplemental oxygen and continue to be assessed.

If a difficult airway is known or suspected, the anesthesiologist should:

- Inform the patient (or responsible person) of the special risks and procedures pertaining to management of the difficult airway.
- Ascertain that there is at least one additional individual who is immediately available to serve as an assistant in difficult airway management.
- Consider the feasibility of supplemental oxygen administration during the process of difficult airway management.

Opportunities for supplemental oxygen administration include (but are not limited to) mask preoxygenation before induction of anesthesia; oxygen delivery by mask, insufflation, or jet ventilation during intubation attempts; and oxygen delivery by mask, blow-by, or nasal cannulae after extubation of the trachea. The uncooperative patient may restrict the opportunities for supplemental oxygen administration, particularly options that involve the application of a mask.

Strategy for Intubation of the Difficult Airway

Specific strategies can be linked together to form more comprehensive treatment plans or algorithms. The cardiopulmonary resuscitation literature provides evidence for the beneficial effects of algorithms in the management of life-threatening cardiac events. The ASA Task Force considers the technical and physiologic complexity of life-threatening airway events to be sufficiently similar to life-threatening cardiac events to encourage the use of algorithms in difficult airway management.

The anesthesiologist should have a pre-formulated strategy for intubation of the difficult airway. This strategy will depend in part upon the anticipated surgery, the condition of the patient, and the skills and preferences of the anesthesiologist.

The strategy for intubation of the difficult airway should include:

- An assessment of the likelihood and anticipated clinical impact of 3 basic problems that may occur alone or in combination:
 - Difficult intubation
 - Difficult ventilation
 - Difficulty with patient cooperation or consent
- A consideration of the relative clinical merits and feasibility of 3 basic management choices:
 - Use of non-surgical vs surgical techniques for the initial approach to intubation
 - Preservation vs ablation of spontaneous ventilation during intubation attempts
 - Awake intubation vs intubation attempts after induction of general anesthesia
- The identification of a primary or preferred approach to:
 - Awake intubation
 - The patient who can be adequately ventilated but is difficult to intubate.
 - The life-threatening situation in which the patient cannot be ventilated or intubated
- The identification of alternative approaches that can be employed if the primary approach fails or is not feasible

A common factor preventing successful tracheal intubation is the inability to visualize the vocal cords during direct laryngoscopy. Many devices and techniques are now available to circumvent the problems encountered with a difficult airway using conventional laryngoscopy.

Rational choices for difficult airway management:

- **Limited mouth opening:** fiberoptic,

light wand, rigid scope, nasal intubation

- **Short neck:** Eschmann stylette, Fast-Trach intubating laryngeal mask airway (ILMA), ViewMax and GlideScope
- **Bloody airway:** retrograde, light wand, ILMA
- **Cannot intubate, cannot ventilate! (CICV):** laryngeal mask airway (LMA), Combitube, Transtracheal jet ventilation (TTJV), Rusch Easy Tube
- **Complete supraglottic obstruction:** cricothyrotomy!

Fiberoptic Bronchoscope

Flexible fiberoptic endoscopy and intubation has revolutionized airway management. Fiberoptic intubation represents a significant advance in management of the difficult airway. It has become more widely utilized in the last 10 years due to increased training and the use of video monitoring for demonstration. In contrast to laryngoscopy utilizing traditional retraction blades, flexible fiberoptic laryngoscopy is characterized by a limited field of view and requires a special fund of knowledge. It is a skill that is not only useful in safely intubating a patient with a difficult airway, but has many other applications in anesthesia and intensive care. Although fiberoptic intubation can be done in the unconscious individual, it is particularly suited to the awake patient and, with proper technique, provides minimal discomfort while maintaining a wide margin of safety. It is considered the “gold standard” for truly difficult situations and allows endotracheal tube placement in patients with distorted anatomy.

Disadvantages of fiberoptic intubation involve the time needed for preparation of the patient and the bronchoscope. Secretions or blood may obscure the anatomy that must be visualized for airway placement. Unless the patient is breathing spontaneously it is difficult to maintain oxygenation during the scope passage and lastly, the fiberoptic scope is expensive to repair when damaged.

Rigid Fiberoptic Laryngoscopes

Rigid fiberoptic laryngoscopes allow visualization of the glottis when there is an inability to align the oral, pharyngeal, and laryngeal axes. This is often due to limited flexion or extension of the neck. These devices (Bullard, laryngoscope, UpsherScope, and WuScope) allow endotracheal intubation with little or no head movement. The devices have an anatomic shape that allows easy placement with limited mouth opening. In one study the Bullard laryngoscope caused less head extension than conventional laryngoscopes and resulted in a better view. Rigid scopes have been especially useful when managing patients with potentially unstable cervical spines. Each is a sturdy piece of equipment, which is difficult to break compared to the fiberoptic scope. Rigid scopes do require practice for proficiency, especially when passing the endotracheal tube.

Lighted Stylet

Transillumination of the anterior neck produces a “bright glow” in the trachea. This is the principle behind lighted stylettes, which allow blind intubation when correctly placed through the glottis. The lighted stylette may be used for routine intubations and appears to be less stimulating than direct laryngoscopy. It is quite useful in patients with limited mouth opening and reduced neck flexion or extension. The Rusch Trachlight Lightwand is the most advanced of this class of device and is useful in avoiding dental injury in patients with expensive and/or protruding teeth. It does not require visualization of the larynx and is

Table 5. Techniques for difficult ventilation

- Esophageal-tracheal Combitube or Easy Tube
- Intratracheal jet stylet
- Laryngeal mask
- Oral and nasopharyngeal airways
- Rigid ventilating bronchoscope
- Surgical airway access
- Transtracheal jet ventilation
- 2-person mask ventilation

portable and inexpensive. Mastery of the technique is required for use in the failed intubation.⁵ Disadvantages involve the potential to cause trauma to tissue because it is a blind technique. It may be difficult to view the light in a patient with dark skin or scarred tissue, and often requires a darkened environment, which is not always feasible.

Shikani Stylete

An evolution of the lighted stylete, this device is actually an endoscope with a malleable stainless steel sheath, which can be inserted through a tracheal tube allowing intubation to be performed under direct vision. The Shikani stylete allows visualization of the glottis and ETT passage during intubation. It is minimally stimulating and useful for patients with limited neck movement, small chin or failed intubation. It can be attached to a monitor like the fiberoptic bronchoscope, but is otherwise portable and less expensive. It requires practice for expertise in an urgent situation, and may be challenging in patients with excessive airway soft tissue.⁶

GlideScope

Essentially a “video laryngoscope,” the GlideScope incorporates a high-resolution digital camera located in the middle of the blade tip. The blade forms a 60-degree angle, which provides a superior, unobstructed view to that obtained with a conventional laryngoscope. The glottis is visualized through a video cable, using an LCD monitor. This device is easy to learn; the skill is intuitive and similar to direct laryngoscopy. It also allows others to see the view and assist the laryngoscopist. Studies and clinical experience have demonstrated that the Glidescope frequently improves the laryngoscopy view

and is useful in patients with limited neck movement.⁷ It does require some degree of mouth opening for manipulation, and practice is needed to improve “hand-eye” coordination. A similar device is the Video Macintosh system by Storz.

ViewMax

Viewmax is a new patented lens system that enhances visualization of the vocal cords by one grade even in difficult cases (Figure 2). The lens refracts the image approximately 20 degrees from the horizontal allowing the user a more anterior view of the larynx. ViewMax provides a clear view of the vocal cords even as the tube passes through.

Bag and mask ventilation

Bag and mask ventilation is an important clinical skill to master. It is frequently the first step in elective airway management of the obtunded or anesthetized patient. It is also the next step following failed intubation. This is the least invasive airway management maneuver and can be sustained for long periods, particularly when there is adequate mask fit. Mask ventilation may produce gastric inflation when not performed properly, placing the patient at risk for regurgitation of gastric contents. Mask ventilation can be optimized by the use of oropharyngeal or nasopharyngeal airways, proper head positioning, and occasionally the assistance of another person. Following prolonged bag and mask ventilation, a nasogastric tube may be used to vent any air that has been forced into the stomach. Difficult mask ventilation may occur in patients who are elderly, obese and have a history of snoring. (Table 5)

Laryngeal mask airway

The LMA is an alternative airway device used for anesthesia and airway support. It consists of an inflatable silicone mask and rubber connecting tube. This device was the first supraglottic airway that became regularly used in clinical practice. It is a useful device because it allows rapid airway access for spontaneous or controlled ventilation and does not re-



Figure 2. ViewMax

quire laryngoscope for placement. It is more easily tolerated at lighter anesthetic planes and is associated with less coughing and bucking compared to endotracheal intubation.

Disadvantages include the potential for regurgitation and aspiration in patients with gastric contents. The LMA may not fully protect the airway in patients at risk for aspiration. There is also the potential for gastric inflation and the inability to ventilate patients at high positive pressures. While the LMA can in no way be a substitute for the endotracheal tube, it can be used in a number of situations where a tracheal tube would have been difficult or impossible to insert.⁸ The classic LMA can also be used as a conduit for fiberoptic intubation in a rescue airway technique. The ILMA was designed to facilitate intubation with its anatomical shape and special lifting bar. The classic LMA as well as the ILMA can be inserted in a variety of patient positions.

While the ILMA has been used extensively as a device for airway management in patients with limited neck movement, its role in the failed intubation scenario was demonstrated by Combes and colleagues.⁹ In their prospective study of unanticipated difficult intubation, they concluded that the ILMA and the gum elastic bougie are effective to solve most problems occurring during unexpected difficult airway management.

Combitube

The Esophago-tracheal Combitube (ETC) is a supraglottic airway device that is designed to function as an alternative to ventilation via mask and tracheal intubation. Like the LMA, the Combitube is

Table 6. Predictors of difficult mask ventilation

- Age over 55 years
- Body mass index exceeding 26 kg/m²
- Presence of a beard
- Lack of teeth
- History of snoring

recommended as a primary rescue device in “cannot intubate / cannot ventilate” situations by the European Resuscitation Council, the American Heart Association, and the American Society of Anesthesiologists. It is considered an alternative to conventional airway management devices in difficult and emergency airway management.¹⁰ When compared to conventional laryngoscopic intubation, it can be easily and promptly inserted; it may be inserted blindly or under direct visualization; and it provides adequate ventilation and oxygenation when situated in the esophageal or tracheal position.

Easy Tube

A new product, Rusch Easy Tube is another double lumen airway device that is designed for emergency or difficult intubation, providing sufficient ventilation from placement in either the esophagus or the trachea. Easy Tube is completely latex-free and incorporates a latex-free pharyngeal cuff and a PVC tracheal/esophageal cuff at the distal end. Easy Tube is a single lumen tube at the distal end so that upon successful intubation, the potential to cause trauma is significantly reduced.

Follow-Up Care

The anesthesiologist should document the presence and nature of the airway difficulty in the medical record. The intent of this documentation is to guide and facilitate the delivery of future care. Aspects of documentation that may prove helpful include (but are not limited to):

- A description of the airway difficulties that were encountered. If possible, the description should distinguish between difficulties encountered in mask ventilation and difficulties encountered in tracheal intubation
- A description of the various airway management techniques that were employed. The description should indicate the extent to which each of the techniques served a beneficial or detrimental role in management of the difficult airway

The anesthesiologist should inform the patient (or responsible person) of the airway difficulty that was encountered. The intent of this communication is to provide the patient (or responsible person) with a role in guiding and facilitating the delivery of future care. The information conveyed may include (but is not limited to) the presence of a difficult airway, the apparent reasons for difficulty, and the implications for future care.

The anesthesiologist should evaluate and follow the patient for potential complications of difficult airway management. These complications include edema, bleeding, tracheal and esophageal perforation, pneumothorax, and aspiration.

Conclusion

The difficult airway continues to be an unexpected challenge in acute care medicine. Having a plan for management can reduce potential complications and improve outcome. The Difficult Airway Algorithm has had an impact on the number of respiratory-related malpractice lawsuits and continues to be refined. The role of alternative airway devices for the difficult airway has been discussed and explored. Specific airway management techniques are greatly influenced by individual disease and anatomy, and successful management may require combinations of devices and techniques. It is important for the clinician to gain management skill in the normal airway whenever possible.

References:

- 1: American Society of Anesthesiologists Task Force on Management of the Difficult Airway. Practice guidelines for management of the difficult airway: an updated report by the American Society of Anesthesiologists Task Force on Management of the Difficult Airway. *Anesthesiology* 2003;98:1269-77.
2. Benumof JL. Management of the difficult adult airway. With special emphasis on awake tracheal intubation. *Anesthesiology* 1991;75:1087-110.
- 3: Ezri T, Szmuk P, Warters RD, et al. Difficult airway management practice patterns among anesthesiologists practicing in the United States: have we made any progress? *J Clin Anesth.* 2003;15:418-22.
4. Cohn AI, Zornow MH. Awake endotracheal intubations in patients with cervical spine disease: A comparison of the Bullard laryngoscope and fiberoptic bronchoscope. *Anesth Analg* 1995; 81:1283-6

5. Hung OR, Pytka S, Morris I, Murphy M, Stewart RD. Lightwand intubation: II--Clinical trial of a new lightwand for tracheal intubation in patients with difficult airways. *Can J Anesth* 1995;42:826-30.
6. Agro F, Cataldo R, Carassiti M, Costa F. The seeing stylet: a new device for tracheal intubation. *Resuscitation* 2000; 44:177-80.
7. Cooper RM. Use of a new videolaryngoscope (GlideScope®) in the management of a difficult airway: [L'usage d'un nouveau vidéolaryngoscope (GlideScope®) pour une intubation difficile]. *Can J Anesth* 2003;50:611-13.
8. Ferson DZ, Rosenblatt WH, Johansen MJ, Osborn I, Ovassapian A. Use of the intubating LMA-Fastrach in 254 patients with difficult-to-manage airways. *Anesthesiology* 2001;95:1175-81.
9. Combes X, Le Roux B, Suen P, et al. Unanticipated difficult airway in anesthetized patients: prospective validation of a management algorithm. *Anesthesiology* 2004;100:1146-50.
10. Agro F, Frass M, Benumof JL. Current status of the Combitude: a review of the literature. *J Clin Anesth* 2002; 14:307-14.

Irene P. Osborn, MD

Dr. Osborne is Associate Professor of Anesthesiology and Director of the Division of Neuroanesthesia at the Mount Sinai School of Medicine, New York. She has authored or coauthored many articles, abstracts, and book chapters in the area of anesthesiology over the past two decades. She was presented with the 1992-1993 “Best Teacher” Award by residents of the Albert Einstein Program, Albert Einstein College of Medicine, Bronx, New York.

Clinical Foundations is a serial education program distributed free-of-charge to health professionals. *Clinical Foundations* is published by Saxe Healthcare Communications and is funded through an education grant from Hudson Respiratory Care Inc., a Teleflex Medical company. The goal of *Clinical Foundations: A Patient-Focused Education Program for Respiratory Care Professionals* is to present clinically- and evidenced-based practices to assist the clinician in making an informed decision on what is best for his/her patient. Opinions expressed in *Clinical Foundations* are those of the authors and not necessarily of the editorial staff of Saxe Healthcare Communications or Hudson Respiratory Care Inc. The publisher and Hudson Respiratory Care Inc., disclaim any responsibility or liability for such material. Clinicians should also consult the medical literature. We welcome opinions and subscription requests from our readers.

Please direct your correspondence to:

Saxe Healthcare Communications
P.O. Box 1282
Burlington, VT 05402
info@saxecommunications.com
Fax: 802.872.7558

Prehospital Management of the Difficult Airway

By Prasanthi Ramanujam, MD and Gary M. Vilke, MD

Note for EMS personnel: This article is an introduction to the management of the difficult airway. CECBEMS recommends that EMS providers access additional information and skills practice including, but not necessarily limited to, capnography assessment and cricothyrotomy procedures.



See page 12

Airway management is a critical skill for prehospital providers. To effectively and efficiently use this skill in an emergency setting, providers must have knowledge and proficiency in the use of several different airway devices. In this article, we will describe the methods of identifying potentially difficult airways, highlight some of the rescue airway devices available to manage patients with difficult airways, and discuss the importance of confirmation of endotracheal intubation. This article is directed towards basic and advanced level prehospital providers. Individual practice should be dictated by state and local policies.

The first step in airway management is to identify the need for supporting the patient's airway. Indications for airway support are often grouped into three categories, including (1) loss of airway protection, (2) inability to effectively oxygenate or ventilate, and (3) injury or medical condition that may lead to deterioration in clinical status¹. Physical exam findings and conditions that may indicate the need for airway management are presented in table 1.

Once a patient is deemed to require airway support, supplemental oxygenation should be initiated before any invasive attempt to control airway ventilation. Common devices used for oxygenation are nasal cannula, face masks and non rebreather masks. Supplemental oxygen administration can be guided by monitoring devices such as a pulse oximeter. If the patient's condition deteriorates and failure occurs after the use of basic air-

way techniques, advanced airway techniques should be performed by prehospital providers.

The most important ventilatory device for prehospital providers is the Bag Valve Mask (BVM). For many Emergency Medical Services (EMS) systems, BVM may be the only device available for ventilatory support in patients with respiratory failure. Employing the BVM is a skill that must be practiced as it will usually maintain ventilation and salvage those cases for whom more invasive airway techniques fail. Often it can be performed with a single operator. In challenging cases, such as obese patients or patients with facial trauma, a second assistant is extremely helpful to maintain a good mask seal with two hands, while maintaining jaw thrust.

Anatomy and Assessment of the Difficult Airway

Oxygenation and ventilation can be achieved and maintained with an endotracheal tube, rescue airway devices or

with BVM ventilation. Prehospital providers must be able to recognize patients who may be difficult to intubate or difficult to ventilate using BVM.¹ Furthermore, avoiding pre-intubation errors may contribute to improved endotracheal tube placement and better outcomes. In this section, we will briefly discuss the anatomical predictors of difficult mask ventilation and intubation and identify avoidable errors during basic or advanced airway placement in the prehospital setting.

The anatomy of the external nose is formed by the bony vault, cartilage and the lobule. The nasal cavities continue posteriorly as the nasopharynx. The antero-medial aspect of the septum is a very vascular area called the Kiesselbach's plexus. When prehospital providers introduce a nasal trumpet, care should be taken to avoid trauma to Kiesselbach's plexus by pointing the beveled end away from the septum. Additionally, when there is a suspected fracture of the mid-face, placement of nasal trumpets or nasopharyngeal airways should be avoided to prevent penetration into the cranial vault.¹

The most important structures influencing intubation through the oral cavity are the teeth, tongue, jaw and pharynx. Providers should observe for muffled voice, pooling secretions and stridor which may indicate upper airway obstruction which poses an increased risk for intubation. Any abnormality in the facial anatomy can pose a major problem for basic BVM airway management. Facial hair or trauma to the lower face re-

Table 1. Physical findings suggestive of need for intubation. [1, 2]

	Airway protection	Oxygenation and ventilation	Progression of patient's clinical condition
Physical Findings	<ul style="list-style-type: none"> ● Unconscious patient ● Impaired consciousness ● Pooling of secretions in oropharynx ● Lack of normal phonation 	<ul style="list-style-type: none"> ● Apnea or agonal respirations ● Cyanosis ● Labored breathing ● Rapid breathing ● Agitation ● Objective data like hypoxia or increase in end-tidal CO₂. 	<ul style="list-style-type: none"> ● Trauma to head, neck or chest ● Airway trauma like thermal burns, inhalational injury ● Caustic ingestion ● Progression of medical conditions like pulmonary edema, asthma or overdose.

sulting in disruption of the face can impair mask seal. Loss of facial tone, which often occurs in the elderly, can cause higher failure rates due to poor mask seal. Although it appears contra intuitive, a better mask seal can be obtained with dentures in place than without any dental support; however, care must be made to avoid denture displacement, in which case they could become an obstruction. Dentures would need to be removed during any advanced airway attempts. Other situations that may cause major problems during mask ventilation include obstruction from hematomas, airway swelling due to conditions such as Ludwig's angina, and bulky tumors. Obese patients with a body mass index (BMI) > 26 kg/m² and gravid women in their third trimester may be more challenging to ventilate due to excessive tissue in the upper airways causing greater airway resistance, and increased chest wall mass and abdominal size hindering diaphragm expansion. Finally, pulmonary conditions with fluid in or around the lungs, asthma or COPD can pose problems with ventilation even though the mask seal may be good.

The entrance to the laryngeal cavity is formed by the tip of the epiglottis, the aryepiglottic folds, arytenoid cartilages and the posterior commissure between the cartilages. Risk factors that can identify the potential for difficult laryngoscopy (e.g. facial abnormalities involving the lower part of the face, such as micrognathia) should also be viewed as a risk for difficult intubation. The quality of the views of structures during laryngoscopy is typically graded based on the Cormack-Lehane laryngeal view system (figure 1). Grade 1 is visualization of the entire glottic aperture. Grade 2 is when part of the vocal cords and arytenoids are seen. Grade 3 is when only the epiglottis is visible. Grade 4 is when no glottic structures are visible. The importance of the grading system is not for the first attempt at laryngoscopy, but to improve chances of success for subsequent attempts by recognizing the difficulty. For example, if the patient has a grade 3 or 4 airway,

rather than making multiple direct laryngoscopy attempts which will have a lower likelihood of success, the airway operator should consider alternative techniques on subsequent attempts earlier in the course of airway management.

The Mallampati Score has also been used to identify patients who may be more challenging to intubate, and utilizes a cruder scoring system by looking directly at the mouth opening of an obtunded patient in emergency situations. Class 1 and 2 views have the pillars and palate visible and are associated with lower intubation failures. Base of uvula is visible in Grade 3 whereas in grade 4 only the hard palate is visible. Even though failure rates of > 10% has been reported by anesthesiologists for grade 4 view, use of this scale is highly limited in pre hospital and emergency department setting due to patient inability to follow simple commands. Neck collars, severe arthritis or conditions like ankylosing spondylitis cause limited mobility and can impair adequate visualization leading to difficult intubation.

The most important anatomical landmark in the neck is the identification of the thyroid cartilage notch. This landmark is used as a guide for a cricothyrotomy incision. Previous neck surgery, neck hematoma, patient obesity, previous neck radiation therapy or penetrating or blunt neck trauma can all distort this landmark and make normal anatomy identification more challenging.

Difficult Airway Algorithm for Prehospital Providers

Different algorithms have been proposed by emergency medicine physicians and anesthesiologists to manage airways under different situations (i.e. in unresponsive patients, predicted difficult airway, etc.). The prehospital airway algorithm is a single algorithm that emphasizes rapid endotracheal intubation and use of rescue devices in difficult or failed setting.² Even though providers should approach every airway with caution, it is important to anticipate a difficult airway and use a stepwise approach

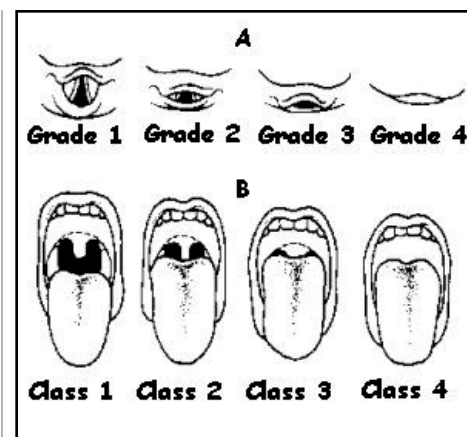


Figure 1. Cormack-Lehane laryngeal view grade system and Mallampati Score

to prevent airway management failure. Once a difficult airway is identified, the next step is to call for assistance. In a pre-hospital setting, this can mean getting help from an additional prehospital provider or informing the receiving hospital to help them prepare for the difficult situation. Thereafter, the provider should maintain adequate oxygenation. This can typically be achieved by providing oxygen supplementation with basic devices, positioning, or BVM. Preoxygenation is very important in a difficult airway to avoid hypoxia and its potential complications during the intubation procedure.

There are several approaches to a difficult airway in the prehospital setting. If there is sufficient oxygenation and a successful trial of mask ventilation, Rapid Sequence Intubation (RSI) can be performed. RSI, defined as intubation facilitated by paralytic medications along with a sedation agent, has been used in pre-hospital systems with reported procedural success, but has been shown to result in worse outcomes in trauma patients.^{3,4} To ensure the success and efficiency of RSI, it is important that prehospital providers have sufficient training, frequency of use, and refresher practice.⁵ The second option is to perform an "Awake Intubation," where the patient is oxygenated, deeply sedated and the glottis is visualized using the laryngoscope blade. If the glottic view is adequate, either a paralytic agent can be administered prior to intubation or the endotracheal tube can be placed without paralyzing the patient based on the operator's judgement. This type of

procedure is rarely used in the prehospital setting.

If the patient is at high risk for a failed intubation based on some of the screening criteria discussed earlier, or there is no visualization of the glottis during awake intubation, the patient should not be paralyzed due to increased risk of a complicated airway failure. If oxygenation can be maintained using BVM, this would be considered an acceptable airway, however, the use of devices like the Laryngeal Mask Airway (LMA), Intubating LMA or Lighted Stylet can also be used to manage these difficult airways, obviating the need to attempt a formal endotracheal airway placement.

Rescue Airway Devices For Difficult Airways

Several airway devices have been introduced over the years to facilitate management of difficult airways. Individuals who are involved in emergency or elective airway management should familiarize themselves in the use of these devices, even though they may not be available to prehospital workers. The prehospital provider should be very familiar and comfortable with the rescue devices that are in their local scope of practice as dictated by the local medical director. This section of the article will describe the various devices available and examples of clinical scenarios where their use would be appropriate.

Devices That Improve Visualization Of The Glottis

Miller and Macintosh blades are the most commonly used laryngoscopic blades. There have been multiple modifications of these blades since the time of their introduction to attempt to meet the challenges of a difficult intubation. Clinical scenarios that may require use of some of these devices include patients with a limited mouth opening, anterior larynx, small intraoral cavity or a rigid or immobile spine.

The Henderson blade has a larger cross-sectional area with an improved tip and offers better visualization of the vo-

cal cords when approached from the corner of the mouth in an oblique direction.

The Viewmax® laryngoscope blade (Rusch, Teleflex Medical, Raleigh, NC) is a modified laryngoscope blade which incorporates an unmagnified optic side port to a standard Macintosh (MAC) blade. This modification allows for an alternative direct view of the glottis from a position 1 cm behind the left tip of the blade while still allowing the standard direct view provided with a MAC-3 blade.

The double angled blade and Dörge's emergency laryngoscope blade (Karl Storz, GMB & Co, KG Tuttlinger, Germany) combine features of the Miller and Macintosh laryngoscope blades. The former with a wider tip helps to manipulate a floppy epiglottis for a better view of the vocal cords.⁶

Flexible tip laryngoscopes are used in situations with a limited mouth opening and restricted head and neck mobility. The compression of a lever helps to lift the epiglottis after placement of the laryngoscope blade.⁷ The Rusch Flipper is a fiberoptic laryngoscope blade that can provide extra anterior exposure during difficult intubations. The articulating tip design allows the end of the blade to be raised by squeezing a lever next to the handle. This one-handed operation can produce a more complete exposure of the glottis.

In patients with an anterior larynx, blades with mirror or prisms help to indirectly visualize the glottic opening (Huffman and Belscope angulated laryngoscopes). The Wisconsin, Flag, and Guedel laryngoscopes are used in patients with a small intraoral cavity. They help to compress the tongue and make the best use of space for visualization.^{6,7}

Indirect laryngoscopy is useful for patients with a limited mouth opening or

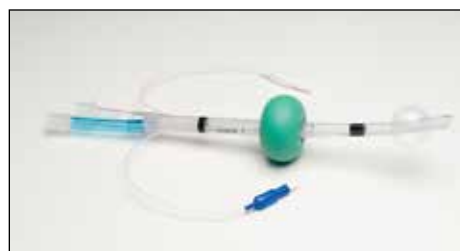

Figure 2. Rusch Easy Tube

restricted neck movement. Unlike conventional direct laryngoscopy, indirect fiber optic laryngoscopy is performed without trying to align the three different axes for intubation. This is particularly useful when a patient has an unstable cervical spine. Bullard Laryngoscope (Circon, ACMI, Stamford, CT) UpsherScope (Mercury Medical, Clearwater, FL) WuScope (Pentax Precision Instrument Corp., Orangeburg, NY) are all examples of indirect laryngoscopes.^{8,9,10}

Although many of these devices are available on the market, most prehospital ground systems will carry Miller and Macintosh laryngoscope blades, with the backup being a supraglottic device, rather than one of these modified blades. Some air transport systems will carry one or two of these devices to improve glottic visualization if the traditional blades fail.

Supraglottic Ventilatory Devices

The Laryngeal Mask Airway (LMA) is one of the more useful rescue devices for difficult and emergency airway management. The LMA consists of a tube that resembles an endotracheal tube and an inflatable mask at the other end. The two cross bars over the mask prevent herniation of the epiglottis into the tube. Ventilation rates were reported to be 100% in the operating room setting and are very high in emergency situations. The LMA Classic is a multi-use device, the LMA Flexible has a non-kinkable tube, and the LMA Pro Seal has a tunnel through which a suction catheter can be passed to aspirate regurgitated material. The LMA Unique is a less expensive disposable device. The ILMA or LMA-Fastrach (facilitates blind intubation with a very high success rate. Two of the disadvantages of the LMA are that it does not constitute definitive airway placement, and patients need a high level of laryngeal anesthesia or must be in a comatose state to tolerate tube placement. The LMA also does not prevent aspiration of gastric contents.^{11,12}

The Combitube is a rescue airway device that is easy to learn for prehospital providers.^{13,14} It is a dual lumen, dual

Table 2. Methods Used to Confirm Endotracheal Tube Placement [20]

Observed	Measured
<ul style="list-style-type: none"> ● Direct visualization ● Chest rise with ventilation ● Breath sounds <ul style="list-style-type: none"> Presence of breath sounds Absence of epigastric sounds ● Misting or condensation of the tube ● Absence of gastric contents in the tube 	<ul style="list-style-type: none"> ● Esophageal Detector Device ● Oxygen saturation ● Capnometry ● Capnography

cuff airway which is most often placed in the esophagus by the blind insertion technique. Once esophageal and oropharyngeal balloons are inflated, the larynx can be ventilated. If placed in the trachea, ventilation is still possible due to the presence of a dual lumen. The available sizes cannot be used in children < 4 feet tall. They should not be used in patients with esophageal pathology, upper airway obstruction, or in an awake patient who cannot tolerate the device placement.

A new product, Rusch Easy Tube is an airway device that is designed for emergency or difficult intubation, providing sufficient ventilation from placement in either the esophagus or the trachea. It has been especially designed for use by EMS/paramedics. Rusch Easy Tube is a double lumen tube with an oropharyngeal cuff and a tracheal/esophageal cuff at the distal end (Figure 2).

The Laryngeal tube airway is a single lumen, multi-use device similar to the Combitube with a blind distal tip and ventilation port between the two cuffs. The Glottic Aperture Seal Airway is inserted using an insertion blade. It seats over the laryngeal inlet creating a seal. There are no pediatric sizes available.^{6,15}

The lighted stylet is a device which can be used when visualization using direct laryngoscope is not achievable. The light source transilluminates the neck and acts as a guide for advancing the endotracheal tube without direct visualization. This procedure requires time for definitive airway placement and hence is not an option when there is an immediate need for oxygenation.^{1,16} Light-guid-

ed intubation using the Rusch Trachlight Stylet and Rusch Tracheal Lightwand can be used for both oral and nasal ETT placement and positioning.

The esophageal introducer, also known as a gum elastic bougie, is a 60-cm long, 15 Fr gauge stylet that is angled 40° at approximately 3.5 cm from the distal end. It is made from a woven polyester base. This is helpful for patients with an anterior larynx. The bougie can be advanced behind the epiglottis, even with partial visualization of glottis. Endotracheal placement can be confirmed by feeling the clicking against the tracheal rings, at which time the endotracheal tube is advanced over the bougie for definitive airway placement.^{7,17}

Confirmation Of Airway Placement

Post intubation management starts with confirmation of the tube placement. One of the most devastating complications associated with endotracheal intubation in a prehospital setting is unrecognized esophageal intubation. The rates of misplaced endotracheal tubes range from 0.4% to 8%.¹⁸ Various methods of confirmation include chest rise with ventilation, auscultation, which has a sensitivity of 94% and specificity of 83% in confirming tube placement in non-arrest, perfusing patients, and direct visualization of the tube passing through the vocal cords (Table 2).¹⁹ Body habitus and lung pathology can limit chest excursion while direct visualization may be affected by vocal cords that are not readily visible or when movement dislodges the tube. Therefore, neither chest excursion nor

direct visualization can be used as a sole confirmation technique.²⁰ By themselves, none of these techniques are 100% sensitive to confirm an appropriately placed endotracheal tube.

Given this lack of sensitivity, more objective measures have been used to better confirm tube placement. Esophageal detector devices such as the Toomey Syringe or self inflating bulb work on the principle that the trachea is firm and does not collapse during air aspiration with the syringe. These devices should be utilized before delivering the first breath to prevent inaccuracies in detection of tube placement. Esophageal detector devices have been shown to be less accurate compared with the end tidal CO₂ detector device for non-cardiac arrest patients in an emergency setting. It's use is also operator-dependent.^{20, 21, 22} Pulse oximetry can help detect hypoxia in esophageal intubations, but are unreliable in patients with poor perfusion states or hypothermia.

End tidal CO₂ (ETCO₂) detection methods are more reliable than other techniques for tube placement. Both qualitative colorimetric and quantitative digital methods can detect CO₂ after a correct tube placement in the trachea. Quantitative ETCO₂ can also be used to monitor inadvertent hyperventilation post airway placement. The use of colorimetric and capnometry devices are limited in cardiac arrest states due to low CO₂ delivery to the lungs. However, capnography with the four phase waveform can detect low levels of CO₂ and offers compelling evidence for correct tracheal tube placement.^{20, 23}

Difficult Pediatric Airways

Pediatric difficult airways are often a challenge for prehospital providers. Not only are they seen less frequently than difficult adult airways, pediatric airways also have a number of anatomical and functional differences among different age groups which are not seen in adult airways. Difficult airways in the pediatric population can result from infectious causes such as epiglottitis and Ludwig's

angina, and non-infectious causes such as trauma, angioedema, foreign body or congenital abnormalities. Interventions by prehospital providers for difficult airways should be based on certain functional principles. One should not attempt intubation in any upper airway obstruction such as angioedema or epiglottitis unless clinical deterioration is imminent. Even small cross-sectional changes along areas of the pediatric airway can translate into very high resistance (about four times) during ventilation.¹ Breathing effort is increased multi-fold when the child cries, thus, prehospital providers should attempt to maintain the child in a comfortable position to avoid precipitating airway obstruction.

Therapeutic options for managing difficult pediatric airways include endotracheal intubation or rescue airway devices for deteriorating situations. Non-invasive modalities such as two-handed mask ventilation with a good seal can be performed in partial upper airway obstruction as in epiglottitis or severe croup. Noninvasive use of BVM is often recommended as the primary method of managing the pediatric airway.²⁴ If noninvasive methods fail and the patient deteriorates, intubation should be attempted. High success rates in pediatric intubation can be achieved in the prehospital setting.²⁵ Use a one size smaller tube in conditions with airway edema like croup. In patients with airway obstruction from a foreign body, attempt to remove it under direct visualization. If unsuccessful and decompensation of clinical condition occurs, intubate and attempt to push the foreign body distally. Needle cricothyrotomy may be indicated in patients with epiglottitis or a lodged foreign body obstruction that cannot be managed by noninvasive measures.²⁶

Summary

Prehospital airway management is different from airway management in the more controlled confines of an emergency department due to limited manpower, space, ancillary support, and alternative airway management options. Hence, it is

important for prehospital providers to be very familiar and comfortable with the available alternative airway devices and to maintain skill in their use during these situations so that they will be prepared when a difficult airway presents itself.

References:

1. Walls RM. Manual of Emergency Airway Management. 2nd ed. Philadelphia, Lippincott William & Wilkins 2004.
2. Wang HE, Kupas DF, Greenwood MJ, et al. An algorithmic approach to prehospital airway management. *Prehosp Emerg Care.* 2005;9:145-55.
3. Davis DP, Ochs M, Hoyt DB, Bailey D, Marshall LK, Rosen P. Paramedic-administered neuromuscular blockade improves prehospital intubation success in severely head-injured patients. *J Trauma.* 2003;55:713-9.
4. Davis DP, Peay J, Sise MJ, et al. The impact of prehospital endotracheal intubation on outcome in moderate to severe traumatic brain injury. *J Trauma.* 2005;58:933-9.
5. Wang HE, Davis DP, Wayne MA, Delbridge T. Prehospital rapid-sequence intubation-what does the evidence show? Proceedings from the 2004 National Association of EMS Physicians annual meeting. *Prehosp Emerg Care.* 2004;8:366-77.
6. Hagberg CA. Special devices and techniques. *Anesthesiol Clin North America* 2002;20:907-32
7. Hagberg CA. Current concepts in the management of difficult airway. *Anesthesiology News.* April, 2004; 35-40
8. Gorbach MS. Management of the challenging airway with the Bullard laryngoscope. *J Clin Anesth.* 1991;3:473-7.
9. Bjoraker DG. The Bullard intubating laryngoscopes. *Anesthesiol Rev.* 1990;17:64-70.
10. Wu TL, Chou HC. A new laryngoscope: the combination intubating device. *Anesthesiology.* 1994;81:1085-7.
11. Asai T, Morris S. The laryngeal mask airway: its features, effects and role. *Can J Anaesth.* 1994;41:930-60.
12. Keller C, Brimacombe J, Bittersohl J, Lirk P, von Goedecke A. Aspiration and the laryngeal mask airway: three cases and a review of the literature. *Br J Anaesth.* 2004; 93:579-82.
13. Davis DP, Valentine C, Ochs M, Vilke GM, Hoyt DB. The Combitube as a salvage airway device for paramedic rapid sequence intubation. *Ann Emerg Med.* 2003; 42:697-704.
14. Ochs M, Vilke GM, Chan TC, Moats T, Buchanan J. Successful prehospital airway management by EMT-Ds using the combitube. *Prehosp Emerg Care.* 2000; 4:333-7.
15. Kurola J, Harve H, Kettunen T, et al. Airway management in cardiac arrest--comparison of the laryngeal tube, tracheal intubation and bag-valve mask ventilation in emergency medical training. *Resuscitation.* 2004;61:149-53.
16. Crosby ET, Cooper RM, Douglas MJ, et al. The unanticipated difficult airway with recommendations for management. *Can J Anaesth.* 1998;45:757-76.
17. Nocera A. A flexible solution for emergency intubation difficulties. *Ann Emerg Med.* 1996;27:665-7.
18. Silvestri S, Ralls GA, Krauss B, et al. The effectiveness of out-of-hospital use of continuous end-tidal carbon dioxide monitoring on the rate of unrecognized misplaced intubation within a regional emergency medical services system. *Ann Emerg Med.* 2005;45:497-503.
19. Grmec S. Comparison of three different methods to confirm tracheal tube placement in emergency intubation. *Intensive Care Med* 2002;28:701-704.
20. O'Connor RE, Swor RA. Verification of endotracheal tube placement following intubation. National Association of EMS Physicians Standards and Clinical Practice Committee. *Prehosp Emerg Care.* 1999;3:248-50.
21. Davis DP, Stephen KA, Vilke GM. Inaccuracy in endotracheal tube verification using a Toomey syringe. *J Emerg Med.* 1999;17:35-8.
22. Takeda T, Tanigawa K, Tanaka H, Hayashi Y, Goto E, Tanaka K. The assessment of three methods to verify tracheal tube placement in the emergency setting. *Resuscitation.* 2003;56:153-7.
23. Davis DP, Dunford JV, Ochs M, Park K, Hoyt DB. The use of quantitative end-tidal capnometry to avoid inadvertent severe hyperventilation in patients with head injury after paramedic rapid sequence intubation. *J Trauma.* 2004;56:808-14.
24. Gausche M, Lewis RJ, Stratton SJ, et al. Effect of out-of-hospital pediatric endotracheal intubation on survival and neurological outcome: a controlled clinical trial. *JAMA.* 2000;283:783-90
25. Vilke GM, Steen PJ, Smith AM, Chan TC. Out-of-hospital pediatric intubation by paramedics: the San Diego experience. *J Emerg Med.* 2002;22:71-4.
26. Stothert JC Jr, Stout MJ, Lewis LM, Keltner RM Jr. High pressure percutaneous transtracheal ventilation: the use of large gauge intravenous-type catheters in the totally obstructed airway. *Am J Emerg Med.* 1990;8:184-9.

Prasanthi Ramanujam, MD

Dr. Ramanujam is a fellow and serves on the clinical faculty of the University of California, San Diego, Department of Emergency Medicine and Emergency Medical Services. She received her MD at the Madras Medical College, in Chennai, Tamil Nadu, India, and served her internship and residency at the Boston Medical Center. Dr. Ramanujam was the 2005 recipient of the David Frommer Award for Academic Excellence at the Boston University Medical Center and has coauthored many papers and abstracts in the area of emergency medicine.

Gary M. Vilke, MD, FACEP, FAAEM

Dr. Vilke is Professor and Director of Clinical Research at the University of California, San Diego (UCSD) School of Medicine, Department of Emergency Medicine. He was the Medical Director for San Diego County Emergency Medical Services. He is author or coauthor of well over a hundred articles, book chapters, and abstracts in the field of emergency medicine and often speaks to medical, paramedical and other professionals on topics related to emergency medicine, including bioterrorism. Dr. Vilke has received many medical and research awards and was listed in San Diego Magazine as one of the "Top Doctors in San Diego County" for both 2004 and 2005.

Questions

EMS answer 1-9 only; RRT answer all questions)

1. Which of the following indicate a need for supporting the patient's airway:

- Loss of airway protection
- Stable patient oxygenating and ventilating within normal limits
- Mild trauma, clinically stable patient.
- Angry patient

2. The following facial feature suggest a difficult airway

- Normal mouth opening
- Swollen tongue
- Body mass index of 22
- Normal Dentition

3. Grade 4 of the Cormack –Lehane classification means

- Vocal cords are visible
- Difficult glottic visualization.
- Arytenoids are visible
- Tracheal bifurcation visible

4. Which of the following are rescue airway devices?

- Fiberoptic laryngoscope
- Combitube
- Endotracheal tube
- Glidescope

5. Surgical Cricothyrotomy should be attempted in

- All edentulous patients
- All difficult airways
- Only in patients > 10 years of age
- All females > 65 years

6. Difficult airway can be managed by

- Bag- Mask ventilation until definitive airway placement
- Multiple attempts until reaching hospital
- Wait until impending cardiac arrest
- Keep airway open using fingers

7. Methods to confirm airway placement include

- Auscultation of lungs and epigastrium
- Percussion of chest wall
- Abdominal exam
- Moving tube in and out of airway

8. Which one of the following is considered highly accurate for tracheal tube placement?

- Toomey Syringe
- Self Inflating bulb
- Colorimetric ETCO₂
- Capnography

9. A lighted stylet is a device that can be used:

- Quickly to replace laryngoscope bulb
- To guide intubation using transillumination of neck
- To create incision for surgical cricothyrotomy
- For post intubation confirmation

10. The principal adverse outcomes associated with the difficult airway include all EXCEPT:

- Brain injury
- Airway trauma
- Severe nausea
- Death

11. The incidence of difficult airway is often increased in:

- Obese patients
- Pediatric patients
- Ambulatory patients
- Obstetrical patients

12. All of the following are potential signs of a difficult airway, EXCEPT:

- History of difficult intubation
- Diagnosis of acid reflux
- Protruding upper teeth
- Limited mouth opening

13. The following is recommended in the event of an anticipated difficult airway:

- rapid sequence induction should always be performed
- the patient should be encouraged to have a local anesthetic
- a capable individual should be asked to serve as an assistant
- The patient should be informed that he/she will remain intubated afterward

14. In the strategy of difficult airway management, awake intubation:

- Is potentially dangerous because the patient can move
- Can cause additional stress and hypertension if not performed correctly
- Is the best choice for head-injured patients
- Is always performed with a fiberoptic bronchoscope

15. Rational choices for the patient who cannot open his/her mouth include all, EXCEPT:

- Glidescope
- Fiberoptic bronchoscope
- Nasal intubation
- Lightwand

16. The laryngeal mask is contraindicated in:

- Patients with difficult airways
- Patients with latex allergy
- Patients with known gastric contents
- Cases for controlled ventilation

This program has been approved for 2.0 contact hours of continuing education (CRCE) by the American Association for Respiratory Care (AARC). AARC is accredited as an approver of continuing education in respiratory care.

This continuing education activity is approved by the Continuing Education Board for Emergency Medical Services (CECBEMS) for 1 (advanced) CEH.

To earn credit, do the following:

Respiratory Therapists:

Read both articles

EMS:

Read Pre-hospital Management of the Difficult Airway only.

Respiratory Therapists:

Complete the entire post-test.

EMS:

Complete questions 1- 9 only in post-test.

Respiratory Therapists & EMS:

- Mark your answers clearly with an "X" in the box next to the correct answer. You can make copies.
- Complete the participant evaluation.
- This test must be taken online at www.clinicalfoundations.org/cf.
- To earn 2.0 CRCE or 1 CEH, you must achieve a score of 75% or more. If you do not pass the test you may take it over one more time.
- Your results will be sent within four weeks after forms are received.
- The fee has been waived through an unrestricted educational grant from Hudson Respiratory Care Inc., a Teleflex Medical company.
- Answer forms must be postmarked by Jan. 6, 2018 (RTs). Please consult www.clinicalfoundations.org for current annual renewal dates.

Participant's Evaluation

The goal of this program is to educate healthcare professionals on the management of the difficult airway in pre hospital and hospital settings.

1. What is the highest degree you have earned? Circle one.

- Diploma
- Associate
- Bachelors
- Masters
- Doctorate

2. Indicate to what degree you met the objectives of this program:

Objectives

Upon completion of the course, the reader was able to:

1. Identify 3 criteria for airway intubation

Strongly Agree Strongly Disagree
1 2 3 4 5 6

2. List at least 3 ways to manage the difficult airway

Strongly Agree Strongly Disagree
1 2 3 4 5 6

3. Explain the Cormack-Lehane laryngeal view system

Strongly Agree Strongly Disagree
1 2 3 4 5 6

4. Identify the methods to confirm airway placement

Strongly Agree Strongly Disagree
1 2 3 4 5 6

5. Describe the ASA difficult airway algorithm.

Strongly Agree Strongly Disagree
1 2 3 4 5 6

6. Identify patients with a potentially difficult airway

Strongly Agree Strongly Disagree
1 2 3 4 5 6

7. Formulate a plan for management of the difficult intubation

Strongly Agree Strongly Disagree
1 2 3 4 5 6

Please indicate your agreement with the following statement. "The content of this course was presented without bias of any commercial product or drug."

Strongly Agree Strongly Disagree
1 2 3 4 5 6

Answers

1	A	B	C	D	9	A	B	C	D
	<input type="checkbox"/>	<input type="checkbox"/>	<input type="checkbox"/>	<input type="checkbox"/>		<input type="checkbox"/>	<input type="checkbox"/>	<input type="checkbox"/>	<input type="checkbox"/>
2	A	B	C	D	10	A	B	C	D
	<input type="checkbox"/>	<input type="checkbox"/>	<input type="checkbox"/>	<input type="checkbox"/>		<input type="checkbox"/>	<input type="checkbox"/>	<input type="checkbox"/>	<input type="checkbox"/>
3	A	B	C	D	11	A	B	C	D
	<input type="checkbox"/>	<input type="checkbox"/>	<input type="checkbox"/>	<input type="checkbox"/>		<input type="checkbox"/>	<input type="checkbox"/>	<input type="checkbox"/>	<input type="checkbox"/>
4	A	B	C	D	12	A	B	C	D
	<input type="checkbox"/>	<input type="checkbox"/>	<input type="checkbox"/>	<input type="checkbox"/>		<input type="checkbox"/>	<input type="checkbox"/>	<input type="checkbox"/>	<input type="checkbox"/>
5	A	B	C	D	13	A	B	C	D
	<input type="checkbox"/>	<input type="checkbox"/>	<input type="checkbox"/>	<input type="checkbox"/>		<input type="checkbox"/>	<input type="checkbox"/>	<input type="checkbox"/>	<input type="checkbox"/>
6	A	B	C	D	14	A	B	C	D
	<input type="checkbox"/>	<input type="checkbox"/>	<input type="checkbox"/>	<input type="checkbox"/>		<input type="checkbox"/>	<input type="checkbox"/>	<input type="checkbox"/>	<input type="checkbox"/>
7	A	B	C	D	15	A	B	C	D
	<input type="checkbox"/>	<input type="checkbox"/>	<input type="checkbox"/>	<input type="checkbox"/>		<input type="checkbox"/>	<input type="checkbox"/>	<input type="checkbox"/>	<input type="checkbox"/>
8	A	B	C	D	16	A	B	C	D
	<input type="checkbox"/>	<input type="checkbox"/>	<input type="checkbox"/>	<input type="checkbox"/>		<input type="checkbox"/>	<input type="checkbox"/>	<input type="checkbox"/>	<input type="checkbox"/>

This test must be taken online at:
www.saxetesting.com/cf